

Primary bladder lymphoma

ABSTRACT

Primary urinary bladder lymphomas are rare, the vast majority of these are B type lymphocytes. This paper reports the case of a 31-year-old male patient who presented a history of gross haematuria. Cystoscopy revealed a large fixed mass located at the trigone. A resection of the mass was performed. Histology showed infiltration of malignant lymphoid cell with plasmacytoid features. The cells showed immunoreactivity to CD45 and CD20 and were negative to CD3, CD5, CD10, CD23. The tumor was classified as extranodal marginal zone lymphoma of mucosa-associated lymphoid tissue type. A thorax, abdomen and pelvis CT scan showed no evidence of systemic disease and a bone marrow biopsy was normal. Four years after receiving radiotherapy treatment, the patient has been well without evidence of recurrent disease. A new CT scan and cystoscopy were performed with negative results. Due to radiosensitivity of lymphomas, treatment may be applied with low doses of radiation with highly reduced morbidity results.

Key words: primary malignant lymphoma of the urinary bladder, lymphomas of mucosa associated lymphoid tissue (Malt) type, radiotherapy.

Francisco Figueroa-Sandoval¹
Patricio Peña-Peña²

¹ Instituto Regional de Tratamiento del Cáncer, Ciudad Juárez, Chihuahua.

² Departamento de Patología, Hospital de Especialidades, Centro Médico de Occidente, IMSS, Guadalajara, Jalisco.

Linfoma primario de vejiga

RESUMEN

Los linfomas primarios de vejiga urinaria son poco frecuentes, la mayor parte son linfomas de linfocitos B. Se comunica el caso de un paciente de 31 años de edad, con hematuria, exclusivamente, sin síntomas b ni síndrome tumoral. El estudio cistoscópico mostró un nódulo en la vejiga urinaria, la biopsia de resección evidenció linfocitos proliferantes grandes semejantes a centrocitos y con diferenciación plasmocitoide, el panel de estudio de inmunohistoquímica fue CD20 +, CD45 +, CD3, CD5, CD10 y CD23 negativos, por lo que se llegó al diagnóstico de linfoma tipo maltoma, los estudios de extensión resultaron negativos. Después de la resección, el paciente recibió radioterapia en la pelvis con acelerador lineal a dosis de 4,000 cGy; los estudios postratamiento no demostraron datos de actividad tumoral. Después de un seguimiento de 48 meses los estudios cistoscópico y radiográficos han sido negativos. La revisión de la bibliografía avala que debido a la radiosensibilidad de los linfomas, el tratamiento puede ser con radioterapia a dosis bajas, con evolución favorable y sin morbilidad.

Palabras clave: linfoma primario de vejiga urinaria, linfomas de mucosa asociados con tejido linfoide tipo maltoma, radioterapia.

Received: January 10, 2014

Accepted: April 25, 2014

Correspondence: Francisco Figueroa Sandoval
Profesor Manuel Díaz 725 Zona Pronaf
32315 Ciudad Juárez, Chihuahua
franfigueroa@irtcancer.com

This article must be quoted

Figueroa-Sandoval F, Peña-Peña P. Primary bladder lymphoma. Rev Hematol Mex 2014;15:76-79.

BACKGROUND

Primary presentation of lymphoma of the bladder is rare.¹⁻⁵ So far in the medical literature less than 100 cases have been reported. The diagnosis of primary lymphoma of the bladder requires exclusion of systemic lymphoma with bladder involvement. This is the first report of case of primary bladder lymphoma in Mexico. Immunoreaction studies and classification schemes according to the Revised European-American Lymphoma Study Group are included in this report.

CASE REPORT

A 31-year-old male presented with a four-month history of frank hematuria and dysuria. An intravenous urography showed a filling defect in the bladder (Figure 1). Cystoscopy revealed a large, solid lesion at the trigone. Resection of the mass was performed. The histology revealed a malignant lymphoma of the bladder. The sections showed a diffuse infiltrate of malignant lymphoid cell with plasmacytoid features (Figures 2 and 3). The cells showed immunoreactivity CD20+, CD45+ and were negative to CD3, CD5, CD10 and CD23. A computer tomography (CT) scan of the thorax, abdomen and pelvis showed no evidence of systemic disease. A bone marrow aspirate was normal. The patient was staged IAE. He was referred to the oncology service and received radiotherapy to the bladder and pelvis (40 Gy in 20 fractions) and was monitored with cystoscopy once a year. The patient was last checked in the forty-eight month after his last radiation treatment and evidence of recurrence was not found. Also a CT (Figure 4) and instrumental biopsy were negative.

DISCUSSION

Primary lymphoma of the bladder is rare. The typical patient presenting with primary bladder

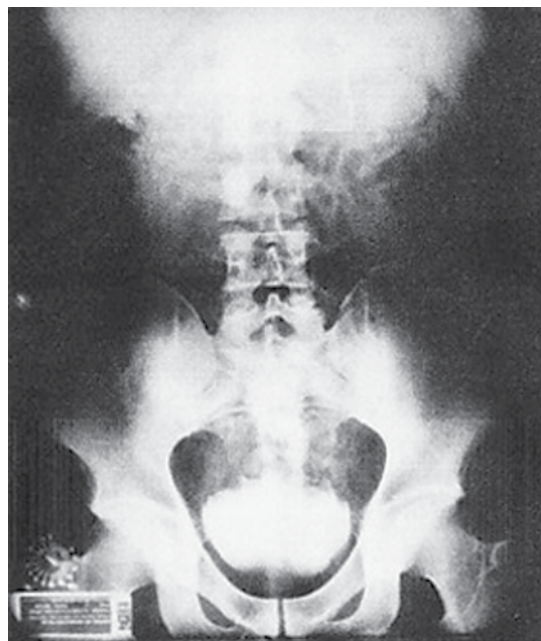


Figure 1. Intravenous urography shows a defects of the urinary bladder.

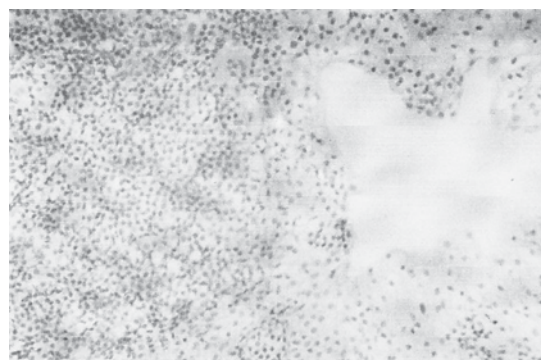


Figure 2. Transitional epithelium is invaded and destroyed by discrete aggregates of lymphoma cell.

lymphoma is female. The age of 50 years, presenting with dysuria and occasionally haematuria. Two-thirds of cases have a filling defect in the bladder. Cystoscopic findings a single exophytic nodule in the trigone.^{4,5} Diagnosis must be

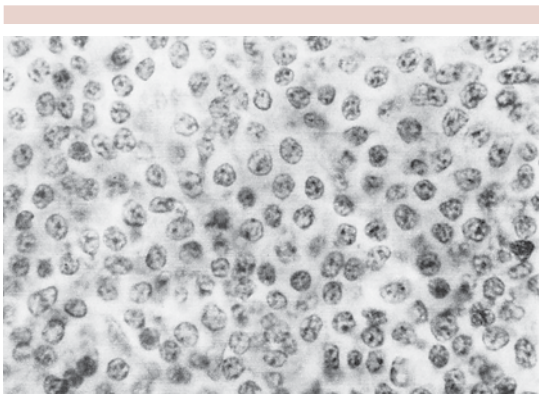


Figure 3. Neoplastic marginal zone B cell with small slightly irregular nuclei with moderate dispersion of chromatin and inconspicuous nucleoli; the pale staining cytoplasm lead to a monocytoid appearance.

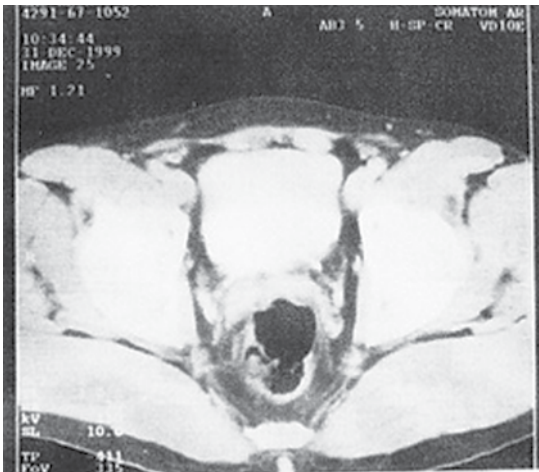

Figure 4. CT scan of pelvis showed no evidence of disease after treatment with radiotherapy.

confirmed by biopsy. These tumours are B cell lineage and are lymphoma of mucosa associated lymphoid tissue (Malt) type.⁴⁻⁶ In the differential diagnosis with other small B cell lymphomas, absence of the characteristic markers for those neoplasms is important: lack of CD5 is useful in distinction from mantle cell and small lympho-

cytic lymphomas, and CD10 in the differential diagnosis with follicular lymphoma.

Due to the small number of reported cases of primary lymphoma of the bladder, treatment is not standardized. In view of the radiosensitivity of lymphoma, treatment included radiotherapy with low doses. However, Gutman et al⁷ favored partial cystectomy, where possible and careful observation with cystoscopy at six month intervals and CT annually.

We do not recommend radical surgery as standard management. Instead radiotherapy or chemotherapy can be applied.⁸⁻¹⁰

Our case was management with local radiotherapy, which seems to have an excellent control of the disease. The results could not be better as the bladder function was preserved.

CONCLUSION

This is a case report of a patient with primary lymphoma of the bladder with an excellent control of the disease with radiotherapy.

ACKNOWLEDGMENT

The authors would like to express gratitude to Osmara Trillo Guerrero and Sonia Mata Valadez.

REFERENCES

1. Aigen AB, Phillips M. Primary malignant lymphoma of urinary bladder. *Urology* 1996;28:235-237.
2. Clarke NW, Maxwell AJ. Primary lymphoma of the urinary bladder *Br J Radiol* 1991;64:761-762.
3. Melekos MD, Matsouka P, Okaefs E. Primary non Hodgkin's lymphoma of the urinary bladder. *Eur Urol* 1992;21:85-88.
4. Bates AW, Norton AJ, Baithim SJ. Malignant lymphoma of the urinary bladder: a clinicopathological study of 11 cases. *J Clin Pathol* 2000;53:458-461.
5. Kempton CL, Kurtin PI, Inward DJ. Malignant lymphoma of the bladder. Evidence from 36 cases that low grade

- lymphoma of the malt type is the most common primary bladder lymphoma. *Am J Sur Pathol* 1997;21:1324-1333.
6. Peistrung RJ, Essell JH, Kurtin PJ. Diversity of organ site involvement among malignant lymphoma of mucosa associated tissue. *Am J Clin Pathol* 1991;15:738-745.
 7. Gutman DA, Malek RS, Chapman WR, Farrow GM. Primary malignant lymphoma of the bladder. *J Urol* 1990;144:1367-1369.
 8. Zinzani P. The many faces of marginal zone lymphoma. *ASH Education Book* December 8. 2012;1:426-432.
 9. Bron D, Van den Neste E, Kentos A, Offner F. BHS guidelines for the treatment of marginal zone lymphomas. *Belg J Hematol* 2014;5:12-21.
 10. Tsang RW, Gospodarowicz MK. Low-grade non-Hodgkin lymphomas. *Semin Radiat Oncol* 2007;17:198-205.