

https://doi.org/10.24245/rev_hematol.v23i3.8212

Molecular mechanisms implicated in the pathogenesis of acute promyelocytic leukemia.

Mecanismos moleculares implicados en la patogénesis de la leucemia promielocítica aguda

Josué Mondragón-Morales, Francisco Neftalí Santos-López

Abstract

Acute promyelocytic leukemia (APL) is a hematological malignancy characterized by an abnormal proliferation of promyelocytes in the bone marrow. One mutation involving chromosomes 15 and 17 leads to an abnormal fusion gene PML/RAR α which causes many of the features of the disease. Symptoms can be unspecific but one of the most common signs of acute promyelocytic leukemia is bleeding. Cytokines released by promyelocytes make an activated state of platelets, besides, chemotherapy can boost this inflammatory response which causes a proinflammatory environment.

KEYWORDS: Acute promyelocytic leukemia; Disseminated intravascular coagulation; Arsenic trioxide; All-trans-retinoic acid.

Resumen

La leucemia promielocítica aguda es una neoplasia maligna hematológica caracterizada por una proliferación anormal de promielocitos en la médula ósea. Una mutación que involucra a los cromosomas 15 y 17 conduce a un gen de fusión PML/RAR α anormal que causa gran parte de las características de la enfermedad. Los síntomas pueden ser inespecíficos, pero uno de los signos más comunes de la leucemia promielocítica aguda es el sangrado. Las citocinas liberadas por los promielocitos hacen que las plaquetas se activen y la quimioterapia puede potenciar esta respuesta inflamatoria, creando un ambiente proinflamatorio.

PALABRAS CLAVE: Leucemia promielocítica aguda; coagulación intravascular diseminada; trióxido de arsénico; ácido retinoico todo trans.

Escuela Superior de Medicina, Instituto Politécnico Nacional, Ciudad de México, México.

Received: August 2022

Accepted: October 2022

Correspondence

Josué Mondragón Morales
josueinfoesm@gmail.com

This article must be quoted: Mondragón-Morales J, Santos-López FN. Molecular mechanisms implicated in the pathogenesis of acute promyelocytic leukemia. Hematol Méx 2022; 23 (3): 159-168.

INTRODUCTION

Acute myeloid leukemia (AML) is the second most frequent hematological malignancy diagnosed in kids and adults. Acute promyelocytic leukemia (APL) is a subtype of acute myeloid leukemia. It's a hematological malignancy that arises from the clonal proliferation of immature cells and accounts for 5-20% of acute myeloid leukemia cases.^{1,2} It's characterized by its morphology (promyelocytes with Auer rods), cytogenetic abnormalities (t(15;17), *PML-RARA*), and its specific treatment (all-trans retinoic acid and arsenic trioxide). World Health Organization classifies myeloid neoplasms based on a combination of clinical, morphological, immunophenotypic, and genetic features to establish their lineage and degree of maturation. **Table 1**

EPIDEMIOLOGY, RISK, AND PROGNOSIS FACTORS

The age-adjusted annual incidence rate of APL is 0.23 per 100,000 persons. The median age of the diagnosis is 44 years.³ There are many risk factors related to APL, like Hispanic patients. The Latino population has a higher proportion of APL (30-38%) versus the non-Latino population (7-10%).^{4,5} Women have a higher incidence, of degenerative disorder (multiple sclerosis), breast, sex organ or hematological cancer, radiation, and topoisomerase II inhibitors treatment history.³

Overexpression of CD56 (10% of total APL) confers reduced 5-year overall survival, high risk of relapse and higher white blood cells (WBC) counts at the diagnosis, which independently has a high risk of early death and relapse

Table 1. World Health Organization (WHO) classification of myeloid neoplasms and acute leukemia²

AML with recurrent genetic abnormalities	AML with t(8;21)(q22;q22.1); <i>RUNX1-RUNX1T1</i>
	APL with t(15;17)(q24.1;q21.2); <i>PML-RARA</i>
	AML with inv(16)(p13.1;q22) or t(16;16)(p13.1;q22); <i>CBFB-MYH11</i>
	AML with t(9;11)(p21.3;q23.3); <i>KMT2A-MLLT3</i>
	AML with t(6;9)(p23;q34.1); <i>DEK-NUP214</i>
	AML with inv(3)(q21.3;q26.2) or t(3;3)(q21.3;q26.2); <i>GATA2, MECOM</i>
	Acute megakaryoblastic leukemia with t(1;22)(p13.3;q13.1); <i>RBM15-MKL1</i>
	AML with t(9;22)(q34.1;q11.2); <i>BCR-ABL1</i>
	AML with <i>NPM1</i> mutation
	AML with biallelic <i>CEBPA</i> mutation
AML, not otherwise specified	AML with <i>RUNX1</i> mutation
	AML with minimal differentiation
	AML without maturation
	AML with maturation
	Acute myelomonocytic leukemia
	Acute monoblastic/monocytic leukemia
	Acute erythroid leukemia
	Acute megakaryoblastic leukemia
	Acute basophilic leukemia
	Acute panmyelosis with myelofibrosis
Myeloid sarcoma	
Myeloid proliferations associated with Down syndrome	Transient abnormal myelopoiesis
	Myeloid leukemia associated with Down syndrome

when is $\geq 10 \times 10^9/L$.⁶ Overweight and obese have a poorer overall survival (OS) and higher risk of differentiation syndrome,⁷ just like the overexpression of CD34 (6). Molecular markers thought-about prognosis factors are the inappropriate expression of CD2 (increased rate of early death), FL3-ITD mutation (is related to increased occurrence of thrombotic events, WBC counts, higher CD34 expression, and increased rate of relapse), DNMT3A, MLL, IDH1, IDH2, and TET2 mutations (are related to reduced overall survival and relapse-free survival [RFS]), low expression of LEF1 (lymphoid enhancer-binding factor 1 have a poor prognosis) and trisomy 8 and abn(7q) (high incidence of coagulopathy, lower thrombocyte counts and higher relapse risk).⁶

MORPHOLOGY, IMMUNOCHEMISTRY AND CYTOGENETICS

There are three variants of APL: classical, atypical and hyperbasophilic variant.

- The classical APL has hypergranular promyelocytes, they contain multiple Auer rods and bilobed nuclei. There is low or absent leukemic cells in peripheral blood, therefore by the designation is required a bone marrow sample.
- The atypical variant has hipogranular/microgranular promyelocytes, some cells can contain Auer rods, they have a bilobed nucleus and there is a zone between the lobes that represents the Golgi zone, which contains granules. The WBC count is higher than in the classical variant.
- The hyperbasophilic variant has promyelocytes with basophilic cytoplasm, with protoplasm blebs, the granules could also be or not visible.²

The APL constitution in most of the cases is CD34-/partial, HLA-DR (-), CD13+, CD33+,

CD11b (-), CD15 (-), CD117 weak positive, (CD2+ and CD56+). The t(15;17)(q22;q21) is detected within 95-98% of cases (8), is identified by fluorescence in situ hybridization (FISH) and reverse transcription-polymerase chain reaction (RT-PCR) testing.¹

PATHOPHYSIOLOGY

Leukemogenesis

PML (promyelocytic gene) is found on chromosome 15. It interacts with p53 (an anti-oncogenic protein) for cellular senescence. RARA gene (retinoic acid receptor alpha) is found on chromosome 17, its function is to manage transcription factors, required for the management of tissue growth, modeling, regeneration, and differentiation of biological process stem cells.^{5,8} The typical chromosomal translocation within the APL is the t(15;17)(q22;q21), that is detected in 95-98% of cases, codifies the fusion oncogenic macromolecule PML-RARA, that is responsible for the myeloid differentiation block at the promyelocyte stage. Downregulation of autophagy-related genes, like ULK1, BECN1, ATG14, ATG5, ATG7, ATG3, ATG4B, and ATG4C, are implicated in the pathophysiology of leukemogenesis and the chemotherapy resistance.⁵

Disseminated intravascular coagulopathy

Disseminated intravascular coagulopathy is an acquired syndrome characterized by uncontrolled activation of coagulation, the consequence is intravascular fibrin formation. Fibrin formation is accompanied by fibrinolysis, which can cause diffuse obstruction of microvasculature.⁹

There are many molecular mechanisms that contribute to microvascular fibrin deposition, such as:

1. Excessive thrombin generation by the overexpression of tissue factor.
2. Platelet activation.
3. Defective anticoagulant pathways.
4. Insufficient fibrin degradation.
5. Inflammatory process.

There are many procoagulant mechanisms implicated in the pathophysiology of the disseminated intravascular coagulation (DIC). Leukemic promyelocytes release cytokines like IL-1 β , IL-6, and TNF- α , which make a “super activated state” of the platelets.¹⁰ Chemotherapy, by its mechanisms, boosts the release of inflammatory cytokines by leukemic necrobiosis and cell death. The consequence of the cytokines’ massive liberation promotes a proinflammatory environment, neutrophils release their intracellular histones as a part of the neutrophil extracellular traps (NETs) and high mobility group box 1 (HMGB1).¹¹

Platelets surfaces overexpress phospholipase in consequence of the interaction between the mentioned three events whereas the neutrophils secrete their extracellular traps, the platelets secrete polyphosphates, which interact with the contact factors, providing polyanionic calcium, required to drive coagulation activation.¹¹ Other mechanisms that have been described in the pathophysiology of the DIC, are hypofibrinogenemia and endothelial cell damage.¹⁰ Leukemic promyelocytes overexpress annexin-II, urokinase-type plasminogen activator (u-PA), and plasmin/ α 2-antiplasmin complex, tissue factors that activate plasminogen. The decreased plasminogen, plasminogen activator inhibitor 1 (PAI-1) and α 2-antiplasmin with the lower concentration of thrombin activatable fibrinolytic inhibitor aggravates fibrinolysis.^{10,11} **Figure 1**

Another mechanism in which leukemic cells contribute to hypercoagulability is the secretion

of tissue factors, cancer procoagulants, and microparticles. The tissue factor interacts with the phosphatidylserine on the APL cell’s surface, activating it. Cancer procoagulant, an aminoacidic peptidase created by the APL cells activates FX and generates thrombin in absence of FVIII.¹⁰

There are new mechanisms that are implicated in the physiopathology of APL and DIC, such as miRNAs and circular RNAs. miRNA is a class of naturally occurring short noncoding RNA molecules, they are implicated in many of genetic and epigenetic processes in the cells, such as differentiation, growth, intracellular homeostasis, and apoptosis.

miRNAs can act as tumor suppressors (i.e., miR-15, miR-16, let-7 and miR-127) or oncogenes (i.e., miR-155, miR-17-92, miR-21, miR-125b, miR-93, miR-143-p3, miR-196b and miR-223) in leukemia.¹²

There is new evidence of abnormal expression of miRNA in malignant hematological diseases. miRNA-181a, miRNA-223, and miRNA-142s are specifically expressed in the hematopoietic system. They regulate directly or indirectly key epigenetic enzymes such as DNA methyltransferase (DNMTs).

miR-126-5p was found to be expressed in leukemia cells, it can induce differentiation in leukemia cells.

The expression level of miR-126-5p was significantly correlated with lactate dehydrogenase level, HGB level, NPM1 mutant type, and complete remission ($p < 0.05$).

Serum miR-126-5p levels are related to the prognosis of patients with APL.¹³

Circular RNAs (circRNA) are powerful regulators of gene expression and participate in the patho-

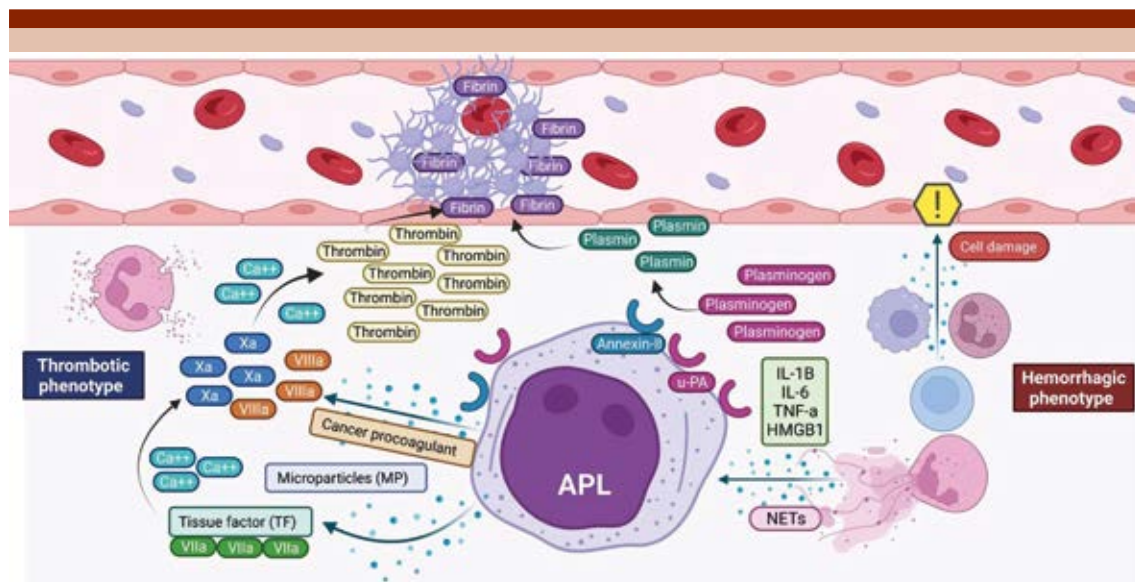


Figure 1. Pathophysiology of disseminated intravascular coagulation in acute promyelocytic leukemia. APL cell overexpresses u-PA and annexin-II (both plasmin activator factors), and the high level of plasmin degrades the fibrin with a high risk of hemorrhagic phenotype. The thrombotic phenotype is characterized by its pro-coagulant and pro-inflammatory microenvironment, caused by the secretion of APL enzymes (cancer procoagulant, tissue factor, and microparticles) that activate the coagulation cascade, and the secretion of pro-inflammatory cytokines. Both phenotypes cause endothelium damage, aggravating coagulopathy, and hemorrhage.¹⁰ APL: acute promyelocytic leukemia; IL-1B: interleukin 1-beta; IL-6: interleukin 6; TNF- α : tumoral necrosis factor-alpha; HMGB1: high mobility group box 1; MP: microparticles; TF: tissue factor; Ca²⁺: calcium; u-PA: urokinase-type plasminogen activator; NETs: neutrophil extracellular traps.

genesis of cancer, especially in all-trans-retinoic acid (ATRA) /arsenic trioxide (ATO) resistance.¹⁴

CLINICAL MANIFESTATIONS

Most of the patients present unspecific symptoms, in 50% of the patients, the initial symptom is asthenia or weakness, and frequently there is also anorexia and weight loss. Fever (10%) or ecchymosis (5%) are rare as an initial symptom.¹⁵

The clinical manifestations could be grouped into different syndromes.

- *Consumptive syndrome:* asthenia, anorexia, weight loss, diaphoresis.

- *Anemic syndrome:* paleness, asthenia, glossitis, headache.
- *Thrombocytopenic syndrome:* ecchymosis, digestive, pulmonary, or intracranial hemorrhage.
- *Infectious syndrome:* fever, recurrent infections, leukopenia.
- *Infiltrative syndrome:* splenomegaly, hepatomegaly, gums, soft tissue, meningeal infiltration, bone pain.

Leukocytosis, *FLT3-ICD* mutations, CD2, and CD15 expression are risk factors for arterial and venous thromboembolism. It's estimated that in

0.9-15% of patients with APL, thromboembolism is the initial presentation. Laboratories can show normocytic normochromic anemia, leukocytosis (the average is 15,000/ μ L, < 5000/ μ L [25-40%] and > 10,000/ μ L [20%]), and thrombocytopenia (< 100,000/ μ L at the diagnosis [75%] and < 25,000/ μ L [25%]).¹⁵

DIAGNOSIS

Some tests used for making a diagnosis are cytology bone marrow aspiration, to directly see the morphological features and quantity of blasts. Karyotype and fluorescence in situ hybridization can also be made to identify chromosome or gene changes. **Table 2** shows several diagnosis methods.

The typical laboratory signature of DIC is characterized by a low platelet count, prolonged global coagulation assays, and increased fibrin degradation products (such as D-dimer).¹⁶ **Table 3**

Diagnosis criteria for DIC are shown in **Table 2**.

Table 2. International Society of Thrombosis and Haemostasia Criteria¹¹

Platelet count/μL	
> 100,000	0
50,000-100,000	1
< 50,000	2
Prolongation of prothrombin time (s)	
< 3	0
3-6	1
> 6	2
Fibrinogen (mg/dL)	
\geq 100	0
< 100	1
D-dimer (μg/mL FEU)	
No increase	0
Moderate increase	2
Strong increase	3
Interpretation:	
• If \geq 5: compatible with overt DIC: repeat daily.	
• If < 5: suggestive for non-overt DIC: repeat in next 1-2 days.	

FEU: fibrinogen equivalent units.

TREATMENT

All-trans retinoic acid (ATRA) is a metabolite of retinol (vitamin A), it acts binding retinoid X receptors (RXR) and retinoic acid receptors (RAR), inducing autophagy by inhibiting mTOR and granulocytic differentiation.²³ One adverse effect is retinoic acid syndrome (RAS): fever, dyspnea, acute respiratory distress, interstitial pulmonary infiltrates, pleural or pericardial effusions, weight gain, peripheral edema, hypotension, renal, hepatic, or multi-organ dysfunction.²⁴ Arsenic Trioxide (ATO) inhibits and degrades Pin1, an oncogenic protein, blocking numerous cancer-driving pathways.²⁵

- Gemtuzumab ozogamicin. It's an anti-CD33 IgG4 monoclonal antibody attached to a cytotoxic moiety. Side effects: Veno-occlusive disease, hepatotoxicity.^{26,27}
- Idarubicin (4-demethoxydaunorubicin), an anthracycline agent, binds to DNA and induces DNA strand breaks. Side effects: Cardiotoxicity, bone marrow aplasia. **Figure 2**

Platelet counts and routine coagulation parameters, prothrombin time, activated partial thromboplastin time and thrombin time, as well as levels of fibrinogen and fibrinogen-fibrin degradation products, should be monitored at least daily.²⁸

INTENSIVE SUPPORTIVE CARE

If the thrombocyte count is over 10-20,000/ μ L, a platelet transfusion is necessary in the absence of overt bleeding.

If the thrombocyte count is over 50,000/mL in patients with active bleeding, it is necessary to have a platelet transfusion.¹⁰

Table 3. Diagnosis methods and its accuracy for APL and DIC

Diagnosis method	Accuracy				Characteristics
	Sensitivity	Specificity	Positive predictive value (PPV)	Negative predictive value (NPV)	
Acute promyelocytic leukemia					
Bone marrow aspiration cytology (BMA)	84.26% ⁻¹⁷ 92.5% ¹⁸	100% ¹⁸	-	-	In accordance with WHO classification, it can be diagnosed AML if there are ≥ 20% of blasts in bone marrow samples or peripheral blood. If there are < 20% of blasts in bone marrow, it can be diagnosed if patients have recurrent cytogenetic abnormalities such as t(15;17), t(8;21), t(16;16) or inv(16) ^{3,19}
Bone marrow imprint cytology (BMI)	97.5% ¹⁶	100% ¹⁸	-	-	
Bone marrow biopsy (BMB)	98.87% ⁻¹⁷ 99.2% ¹⁸	100% ¹⁸	-	-	
RT-PCR	78.6-98.3% ²⁰	100% ²⁰	68-99% ²⁰	90.6-99.8%. 100% [in patients with t(15;17) and t(8;21)] ²⁰	Retro transcriptase-polymerase chain reaction is a test used to detect genetic abnormalities of hematopoietic cells in bone marrow samples
Disseminated intravascular coagulation					
D-dimer concentration ≥ 19,000 ng/μL FEU (fibrinogen equivalent units)	96% (79-100%) ²¹	92% (84-96%) ²¹	74% (55-88%) ²¹	99% (94-100%) ²¹	It's a subtype of coagulation test, D-dimer concentration is determined by immunoturbidimetric assay. ⁹ It is the final product of the degradation of a fibrin-rich thrombus mediated by thrombin, factor XIIIa and plasmin ²²
Schistocytes ≥ 10,000 red blood cells (RBC)	36 (18-58%) ²¹	89% (82-94%) ²¹	39% (24-57%) ²¹	87% (83-90%) ²¹	Schistocyte is an anormal morphology of red blood cell. They can be evaluated by using a microscope to see RBC in a Wright-Giemsa peripheral blood-stained smear

It's necessary to maintain fibrinogen levels above 100-150 mg/dL and platelets until 30-50,000/ μ L with fresh frozen plasma, fibrinogen and/or cryoprecipitate, and platelet transfusions.¹⁰

There is no evidence of the benefit of using heparin, tranexamic acid, or other anticoagulant or antifibrinolytic agents to attenuate the hemorrhagic or thrombotic risk associated with DIC.²⁸

DIFFERENTIATION SYNDROME

Differentiation syndrome is a potentially fatal adverse drug reaction caused by the administration of ATRA, ATO, and IDH-inhibitors, all differentiating agents, in patients with APL. The cumulative incidence was about 10.4% with IDH-inhibitors and 5.9% with retinoic acid derivatives, such as ATRA and ATO.²⁹

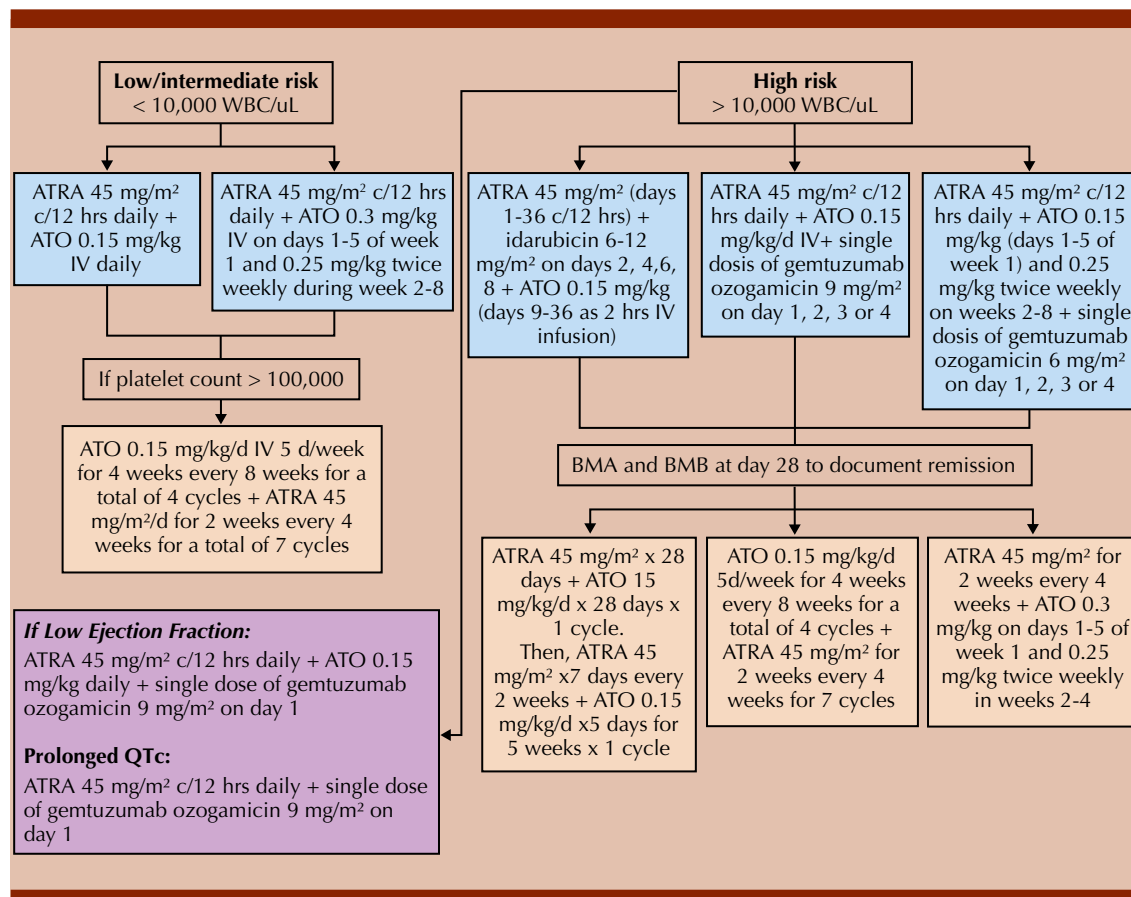


Figure 2. Acute promyelocytic treatment. Acute promyelocytic leukemia is divided into two groups depending on risk stratification. Blue boxes show the preferred regimens of induction chemotherapy, yellow boxes show consolidation chemotherapy, and the red box shows the preferred regimen if the patient has a low ejection fraction and prolonged QTc.

APL: acute promyelocytic leukemia; WBC: white blood cells; ATRA: all-trans retinoic acid; ATO: arsenic trioxide; BMA: bone marrow aspiration; BMB: bone marrow biopsy.^{3,4}

It is diagnosed by the PETHEMA (Programa para el Tratamiento de Hemopatías Malignas) criteria.

ATRA is associated with cell migration, endothelial activation, and tissue damage. Blasts cells secrete proinflammatory cytokines such as IL-6, TNF- α , and interleukin 1- β , enzymes, and adhesion molecules such as Intercellular Adhesion Molecule-1 (ICAM-1), monocyte chemoattractant protein-1 (MCP-1/CCL-2), and type 2 transglutaminase (TGM2/TG2).

Treatment of differentiation syndrome

The management of all differentiation syndrome requires aggressive supportive care.

1. Dexamethasone 10 mg every 12 hrs, increasing the frequency to every 6 hrs if no improvement within 24 hrs.³⁰
2. If the differentiation syndrome (DS) becomes severe or the patient presents organ failure and/or absence of response to

dexamethasone, it's necessary to hold the ATRA/ATO and restart it once the severe DS and any organ failure get resolved.

3. Oxygenation/mechanical ventilation if the patient needs it.
4. Fluid management.
5. Coagulopathy-specific treatment.

REFERENCES

1. Ryan MM. Acute promyelocytic leukemia: a summary. *J Adv Pract Oncol* 2018; 9 (2): 178-87.
2. Bain BJ, Béné MC. Morphological and immunophenotypic clues to the WHO categories of acute myeloid leukaemia. *Acta Haematol* 2019; 141 (4): 232-44. doi: 10.1159/000496097.
3. Pollyea DA, Altman JK, Bhatt BR, Dixby D, Fathi AT. Acute myeloid leukemia. *Cancer Cytogenet* 2010; 45-139.
4. Yilmaz M, Kantarjian H, Ravandi F. Acute promyelocytic leukemia current treatment algorithms. *Blood Cancer J* 2021; 11 (6). <https://doi.org/10.1038/s41408-021-00514-3>.
5. Noguera NI, Catalano G, Banella C, Divona M, Faraoni I, Ottone T, et al. Acute promyelocytic leukemia: Update on the mechanisms of leukemogenesis, resistance and on innovative treatment strategies. *Cancers (Basel)*. 2019; 11 (1591): 1-21. doi: 10.3390/cancers11101591.
6. Testa U, Lo-Coco F. Prognostic factors in acute promyelocytic leukemia: strategies to define high-risk patients. *Ann Hematol* 2016; 95 (5): 673-80. doi: 10.1007/s00277-016-2622-1.
7. Li S, Chen L, Jin W, Ma X, Ma Y, Dong F, et al. Influence of body mass index on incidence and prognosis of acute myeloid leukemia and acute promyelocytic leukemia: A meta-analysis. *Sci Rep* 2017; 7 (1): 1-10. doi: 10.1038/s41598-017-18278-x.
8. Gurnari C, Voso MT, Girardi K, Mastronuzzi A, Strocchio L. Acute promyelocytic leukemia in children: A model of precision medicine and chemotherapy-free therapy. *Int J Mol Sci* 2021; 22 (2): 1-13. doi: 10.3390/ijms22020642.
9. Papageorgiou C, Jourdi G, Adjambri E, Walborn A, Patel P, Fareed J, et al. Disseminated intravascular coagulation: An update on pathogenesis, diagnosis, and therapeutic strategies. *Clin Appl Thromb Hemost* 2018; 24: 85-285. doi: 10.1177/1076029618806424.
10. Ikezoe T. Pathogenesis of disseminated intravascular coagulation in patients with acute promyelocytic leukemia, and its treatment using recombinant human soluble thrombomodulin. *Int J Hematol* 2014; 100 (1): 27-37.
11. Ten Cate H, Leader A. Management of disseminated intravascular coagulation in acute leukemias. *Hamostaseologie* 2021; 41 (2): 120-6. doi: 10.1055/a-1393-8302.
12. Mardani R, Jafari Najaf Abadi MH, Motieian M, Taghizadeh-Boroujeni S, Bayat A, Farsinezhad A, et al. MicroRNA in leukemia: Tumor suppressors and oncogenes with prognostic potential. *J Cell Physiol* 2019; 234 (6): 8465-86. doi: 10.1002/jcp.27776.
13. Zhang B, Pei Z, Wang H, Bai J, Wang J, Zhao Y, et al. Clinical value of serum miRNA in patients with acute promyelocytic leukemia. *J Oncol* 2022; 2022. doi: 10.1155/2022/7315879.
14. Li S, Ma Y, Tan Y, Ma X, Zhao M, Chen B, et al. Profiling and functional analysis of circular RNAs in acute promyelocytic leukemia and their dynamic regulation during all-trans retinoic acid treatment article. *Cell Death Dis* 2018; 9 (6). <http://dx.doi.org/10.1038/s41419-018-0699-2>
15. Zamrodah Y. *Harrisons Principles of Internal Medicine*. 2016; 15 (2): 1-23.
16. Levi M. Pathogenesis and diagnosis of disseminated intravascular coagulation. Vol. 40, *Int J Lab Hematol* 2018; 15-20. doi: 10.1111/ijlh.12830.
17. Parajuli S, Tuladhar A. Correlation of bone marrow aspiration and biopsy findings in diagnosing hematological disorders - a study of 89 cases. *J Pathol Nepal* 2014; 4 (7): 534-8. <https://doi.org/10.3126/jpn.v4i7.10294>.
18. Chandra S, Chandra H. Comparison of bone marrow aspirate cytology, touch imprint cytology and trephine biopsy for bone marrow evaluation. *Hematol Rep* 2011; 3 (3): 4-7. doi: 10.4081/hr.2011.e22.
19. Gilotra M, Gupta M, Singh S, Sen R. Comparison of bone marrow aspiration cytology with bone marrow trephine biopsy histopathology: An observational study. *J Lab Physicians* 2017; 9 (03): 182-9. doi: 10.4103/JLP.JLP_117_16.
20. Aanei CM, Veyrat-Masson R, Selicean C, Marian M, Rigollet L, Trifa AP, et al. Database-guided analysis for immunophenotypic diagnosis and follow-up of acute myeloid leukemia with recurrent genetic abnormalities. *Front Oncol* 2021; 11: 1-14. <https://doi.org/10.3389/fonc.2021.746951>.
21. Shahmarvand N, Oak JS, Cascio MJ, Alcasid M, Goodman E, Medeiros BC, et al. A study of disseminated intravascular coagulation in acute leukemia reveals markedly elevated D-dimer levels are a sensitive indicator of acute promyelocytic leukemia. *Int J Lab Hematol* 2017; 39 (4): 375-83. doi: 10.1111/ijlh.12636.
22. Morales MM, Agramonte Llanes OM, Rodríguez YT. Diagnostic usefulness of quantitative D-dimer. *Rev Cubana Hematol Inmunol Hemoter* 2020; 36 (4): 1-17.
23. Liang C, Qiao G, Liu Y, Tian L, Hui N, Li J, et al. Overview of all-trans-retinoic acid (ATRA) and its analogues: Structures, activities, and mechanisms in acute promyelocytic leukaemia. *Eur J Med Chem* 2021; 220: 113451. <https://doi.org/10.1016/j.ejmech.2021.113451>.

24. Kayser S, Schlenk RF, Platzbecker U. Management of patients with acute promyelocytic leukemia. *Leukemia* 2018; 32 (6): 1277-94. doi: 10.1038/s41375-018-0139-4.
25. Kozono S, Lin YM, Seo HS, Pinch B, Lian X, Qiu C, et al. Arsenic targets Pin1 and cooperates with retinoic acid to inhibit cancer-driving pathways and tumor-initiating cells. *Nat Commun* 2018; 9 (1). <https://doi.org/10.1038/s41467-018-05402-2>.
26. Joubert N, Beck A, Dumontet C, Denevault-Sabourin C. Antibody – drug conjugates: The last decade 2020; 1-31.
27. Goldenson BH, Goodman AM, Ball ED. Gemtuzumab ozogamicin for the treatment of acute myeloid leukemia in adults. *Expert Opin Biol Ther* 2021; 21 (7): 849-62. doi: 10.1080/14712598.2021.1825678.
28. Sanz MA, Montesinos P. Advances in the management of coagulopathy in acute promyelocytic leukemia. *Thromb Res* 2020; 191 (September 2019): S63-7. [https://doi.org/10.1016/S0049-3848\(20\)30399-6](https://doi.org/10.1016/S0049-3848(20)30399-6).
29. Gasparovic L, Weiler S, Higi L, Burden AM. Incidence of differentiation syndrome associated with treatment regimens in acute myeloid leukemia: A systematic review of the literature. *J Clin Med* 2020; 9 (10): 3342. doi: 10.3390/jcm9103342.
30. Stahl M, Tallman MS. Differentiation syndrome in acute promyelocytic leukaemia. *Br J Haematol* 2019; 187 (2): 157-62. doi: 10.1111/bjh.16151.