

[https://doi.org/10.24245/rev\\_hematol.v22i2.5494](https://doi.org/10.24245/rev_hematol.v22i2.5494)

## Oral manifestations in patients with hereditary hemolytic anemias.

### Manifestaciones bucales en pacientes con anemias hemolíticas hereditarias

Paulina Rivera-Salinas,<sup>1</sup> Marco Antonio Rueda-Ventura,<sup>2,4</sup> Laura Beatriz Isidro-Olán,<sup>2</sup> Efraín Zurita-Zarracino<sup>3,5</sup>

#### Abstract

**BACKGROUND:** Hereditary hemolytic anemias are due to structural defects of the membrane as in the molecular content of erythrocyte hemoglobin, which leads to premature death. Among the most frequent hemolytic anemias is sickle cell anemia, hereditary spherocytosis and thalassemia.

**OBJECTIVE:** To know the oral manifestations in patients with hereditary hemolytic anemias for an early diagnosis and personalized stomatological care.

**MATERIALS AND METHODS:** A prospective, observational, cross-sectional, descriptive study was carried out at the Regional Hospital of High Specialty of the Child Dr. Rodolfo Nieto Padrón, Villahermosa, Tabasco, Mexico, in children who attended the hematology and odontopediatrics services of external consultation in the afternoon shift, during the period of June 4<sup>th</sup> to August 8<sup>th</sup>, 2019. An *ad hoc* instrument was designed consisting of three sections, the first to investigate sociodemographic data, a second to know the hematological diagnosis and a third to explore oral manifestations.

**RESULTS:** A total of 10 children and adolescents whose ages ranged from 1 to 13 years were examined; 5 of them belonged to the male sex; of the hereditary hematologic disorders 5/10 had sickle cell anemia and 5/10 hereditary spherocytosis. The most common manifestations were pale mucous membranes, multiple caries, hypomineralization, paleness and jaundice of teguments.

**CONCLUSIONS:** The dentist surgeon must know the oral manifestations in these types of patients, to provide personalized stomatological care according to their needs without jeopardizing their general health.

**KEYWORDS:** Hemolytic anemia; Sickle cell anemia; Spherocytosis; Thalassemia; Hypomineralization.

#### Resumen

**ANTECEDENTES:** Las anemias hemolíticas hereditarias se deben a defectos estructurales de la membrana como en el contenido molecular de hemoglobina eritrocitaria, lo que conduce a la muerte prematura. Entre las anemias hemolíticas más frecuentes están la anemia falciforme, la esferocitosis hereditaria y la talasemia.

**OBJETIVO:** Conocer las manifestaciones bucales en pacientes con anemias hemolíticas hereditarias para establecer el diagnóstico de manera temprana y dar atención estomatológica personalizada.

**MATERIALES Y MÉTODOS:** Estudio prospectivo, observacional, transversal, descriptivo efectuado en el Hospital Regional de Alta Especialidad del Niño Dr. Rodolfo Nieto Padrón, Villahermosa, Tabasco, México, en niños que asistieron a los servicios de Hematología y Odontopediatría de consulta externa en el turno de la tarde, durante el periodo del 4 de junio al 8 de agosto de 2019. Se diseñó un instrumento *ad hoc* que constaba de tres secciones, la primera para investigar datos sociodemográficos, la segunda para conocer el diagnóstico hematológico y la tercera para explorar las manifestaciones orales.

<sup>1</sup> Student of Dentistry College.

<sup>2</sup> Research Professors of Dentistry College.

<sup>3</sup> Research Professor of Medicine College.

Universidad Juárez Autónoma de Tabasco, Tabasco, México.

<sup>4</sup> Pediatric Stomatologist.

<sup>5</sup> Pediatric Hematologist.

Hospital de Alta Especialidad del Niño Dr. Rodolfo Nieto Padrón, Villahermosa, Tabasco, México.

**Received:** March 2021

**Accepted:** May 2021

#### Correspondence

Rueda Ventura Marco Antonio  
ruedaven@hotmail.com

**This article must be quoted:** Rivera-Salinas P, Rueda-Ventura MA, Isidro-Olán LB, Zurita-Zarracino E. Oral manifestations in patients with hereditary hemolytic anemias. Hematol Méx. 2021 April-June; 22 (2): 69-79.

**RESULTADOS:** Se examinaron 10 niños y adolescentes cuyas edades variaron entre 1 y 13 años; 5 de ellos pertenecían al sexo masculino; de los trastornos hematológicos hereditarios, 5/10 tenían anemia de células falciformes y 5/10 esferocitosis hereditaria. Las manifestaciones más frecuentes fueron mucosas pálidas, caries múltiple, hipomineralización, palidez e ictericia de los tegumentos.

**CONCLUSIONES:** El cirujano dentista debe conocer las manifestaciones bucales en este tipo de pacientes para proporcionar una atención estomatológica personalizada de acuerdo con sus necesidades sin poner en riesgo su salud general.

**PALABRAS CLAVE:** Anemia hemolítica; anemia falciforme; esferocitosis; talasemia; hipomineralización.

## BACKGROUND

Hereditary hemolytic anemias are due to structural defects of the membrane as in the molecular content of erythrocyte hemoglobin, which leads to premature death. Hemolytic anemias are characterized by a decrease in the red blood cells life of less than 120 days, with an increase in erythropoiesis at medullar level, causing an increase in reticulocytes peripheral blood.<sup>1</sup>

Among the most frequent hemolytic anemias are sickle cell anemias, hereditary spherocytosis (HS) and thalassemia of the  $\alpha$  or  $\beta$  chains, with some predominance in beta-thalassemia. Hemoglobinopathies represent a problem in the 229 countries considered, representing 71%, in which 89% of all births occur. Globally, 7% of pregnant women are carriers of beta or alpha zero thalassemia or hemoglobin S, C, D, Punjab or E, and more than 1% of couples are at risk.<sup>2</sup>

Sickle cell anemia is highly prevalent in some regions of Africa, Asia and America. Sickle cell anemia affects 1/365 African-American and 1/16,300 Hispanic American.<sup>3</sup> The prevalence of hemoglobin S (HbS) in black and negroid popula-

tion of Latin America is variable, in the case of Brazil it is 6.2%, Colombia 11.9%, Costa Rica 8.1%, Cuba 6.1%, Mexico 11.2%, Panama 16% and Honduras 10%.<sup>4</sup> HS is the most frequent hereditary hemolytic anemia in the world, is particularly frequent in Northern Europe, with a prevalence of 1/500 and an incidence of 1/2,000 in Caucasian population.<sup>5</sup>

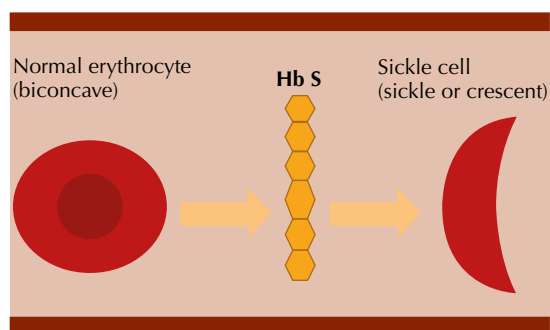
In Mexico, 30% of patients with suspected hemolytic anemia have HS.<sup>6</sup> Also there is a hemoglobinopathies' prevalence of 12.5% to 26.1%, where  $\beta$ -thalassemia and HS are the most frequent findings.<sup>7</sup>

Patients with this type of hemoglobinopathies have hemolytic changes that can influence their oral cavity and cause damage to their oral health as well as their general health. Dentist must know clinical signs of these disorders to apply preventive and personalized dental care according to their needs. Sickle cell anemia or sickle cell disease consists of an autosomal recessive inheritance defect characterized by the presence of hemoglobin S (Hb S). These are genetic disorders by the presence of a mutation in a chain that makes up hemoglobin (Beta globin) that results in Hb S.<sup>8</sup> This is attributed to a mutation in the

corresponding beta chain gene that has been located on chromosome.<sup>9</sup>

Globin S does not have the same ability as a normal globin to transport oxygen to the tissues. The consequence is the formation of Hb S, or  $\beta^6$  Glu-Val, which when deoxygenated, polymerizes and is arranged in rigid and elongated structures, causing erythrocytes take sickle or crescent's shape, which generates blood vessels' occlusion due to erythrocytes' rigidity, increasing blood viscosity and obstruction in the capillary circulation (vaso-occlusive crisis). Red blood cells are abnormally adhesive through interaction with multiple blood cells (neutrophils, monocytes and platelets) and the immune system, promote inflammation, vascular obstruction and endothelium damage, initiating multiple alteration that affect most of the vital organs, Chronic hemolysis generated by damage to the red blood cell membrane caused by insoluble tactiles, releases hemoglobin into circulation, triggers inflammatory phenomena and nitric oxide consumption, responsible for oxidative stress and the release of heme-loades microparticles.<sup>10</sup> **Figure 1**

Hereditary spherocytosis (HS) has been identified in a group of alterations of the erythrocyte membrane, witch ultimately leads to gradual loss of surface area, resulting in spherical erythrocyte, instead of its classic biconcave shape.<sup>11</sup> The



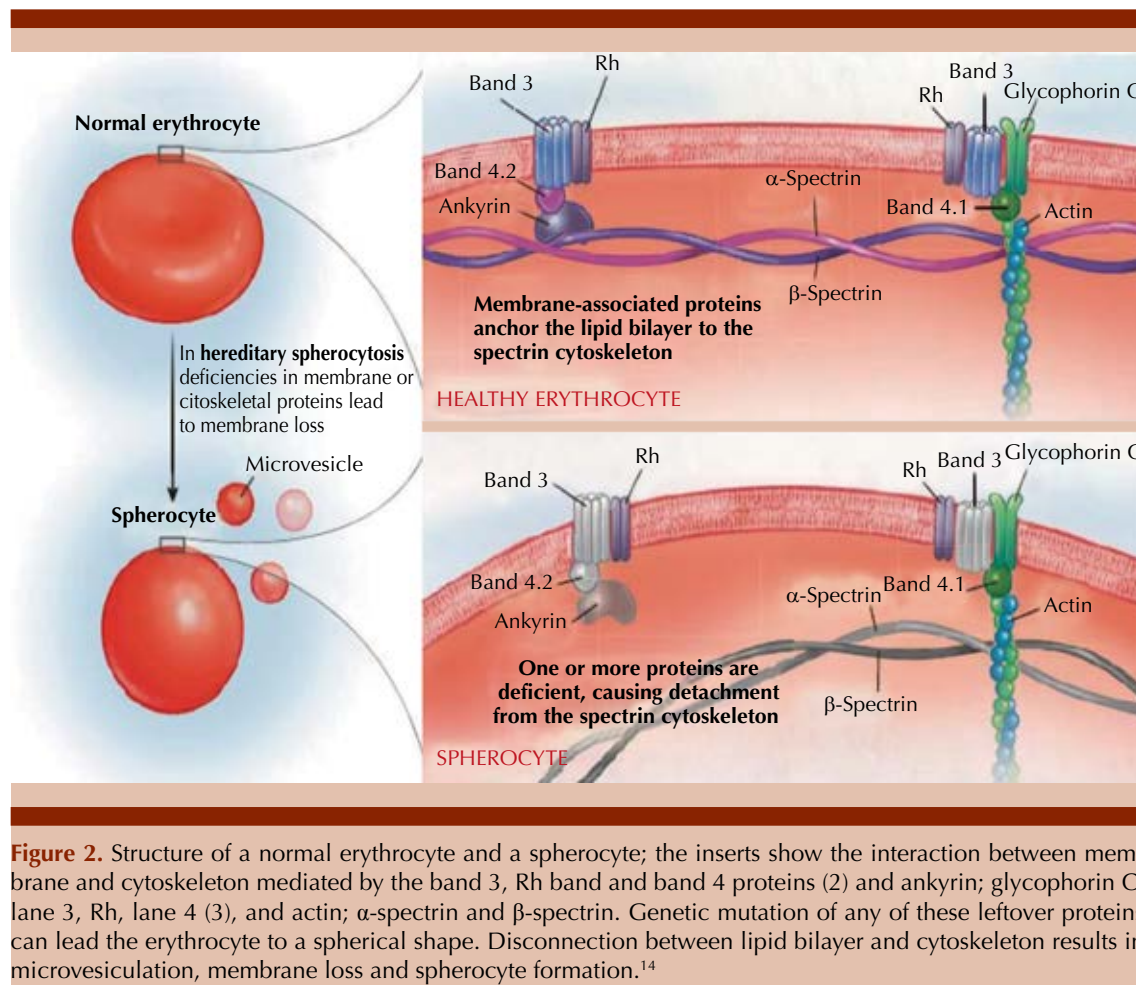
**Figure 1.** As Hb S is deoxygenated, it polymerizes and tactiles form causing stiffness in the red blood cells.

primary molecular defects generates a qualitative or quantitative defect in proteins that are in charge of keeping the cytoskeleton attached to the lipid bilayer. This phenomenon leads to a progressive reduction of membrane surface area, as a consequence, to a change in the red cell shape. HS can be transmitted in an autosomal dominant or recessive manner, and the novo mutation are not uncommon.<sup>12</sup> Molecular defect is heterogeneous, involving genes that encode spectrin, ankirin, band 3 and protein. The deficiency or dysfunction of any of these proteins produces alteration of the membrane's cytoskeleton, erythrocytes are selectively trapped in the spleen.<sup>13</sup> **Figure 2**

Thalassemia is also known as Mediterranean anemia, anemia or Cooley-Jakschs anemia. Thalassemia is one of the blood dyscrasias due to inherited disorders, where the hemoglobin molecule can be altered by the null or deficient decrease in the synthesis of globin chains ( $\alpha$  or  $\beta$ ). Beta thalassemia is caused by a deficiency in the synthesis of the beta chain (also called beta-thalassemia), this is the most frequent worldwide. Alpha thalassemia is equal due to deficiency in alpha chain synthesis (also called alpha-thalassemia) and delta-beta is due to deficiency in synthesis of delta and beta chain.<sup>15</sup>

This occurs within the erythropoietic tissue and therefore results in ineffective erythropoiesis. Some immature red blood cells enter the circulation and due to their membrane defect, they are fragile and prone to hemolysis. They also exhibit impaired deformability and are trapped by the spleen, where they are phagocytosed, causing the growth of the spleen, which implies the development of functional hypersplenism with the elimination of platelets and white blood cells, as well as red blood cells.<sup>16</sup>

The clinical manifestations of these anemias differ in each patient, splenomegaly, low weight



(due to hypoxia), paleness and jaundice of the skin and mucosa is evident when the Hb level drops to 6-8 g/dL. Furthermore, they can be accompanied by jaundice (due to the increased release of bilirubin with the metabolism of Hb), hepatosplenomegaly (as a reflection of hypersplenism and increased extramedullary production of erythrocytes), and in severe cases congestive heart failure.<sup>1,17</sup>

A deficit in weight has been observed near adolescence, as well as a growth deficit that increases with age and is more evident in males than females. Authors believe that the degree of affectation of growth and development is

related to the severity of the clinical case and to hemoglobin F (HbF) levels.<sup>18</sup> Likewise, there may be painful vasocclusive crises (VC), acute chest syndrome (ACS), liver crisis, splenic sequestration crisis, VC of the central nervous system (VC CNS), priapism, malleolar ulcers, dactylitis that presents in childhood,<sup>19</sup> erythroid aplasia and organ-specific complications (bone, lungs, brain, kidney and spleen).<sup>1</sup>

The most frequent form of presentation in HS patients is detected in the first years of life, with anemia, splenomegaly and jaundice, which occasionally requires a transfusion.<sup>20</sup> The clinical forms of HD vary widely, from minimal hemo-

lysis without clinical manifestations to severe hemolysis. Anemia is accompanied by reticulocytes and hyperbilirubinemia, due to marked hemolysis that leads to increased bilirubin levels, babies are prone to have acute bilirubin encephalopathy, also known as kernicterus.<sup>21</sup> Family history, the finding of splenomegaly, and the presence of spherocytes in peripheral blood usually guide the diagnosis definitively.<sup>22</sup>

The clinical manifestations in patients with thalassemia in severe forms are due to anemia and ineffective erythropoiesis, so there will be common signs and symptoms of all anemia, due to an increase in erythroid precursors in the bone marrow such as skeletal disorders and osteoporosis and outside it as liver and splenomegaly and paravertebral masses of extramedullary hemopoiesis. In addition, due to anemia, hypoxia and the expansion of erythropoiesis, there is a decrease in hepcidin that determines an increase in intestinal absorption of iron (Fe) with a secondary iron overload that will be accentuated by transfusions in cases of dependent transfusion. Apart from alterations in the nails: koilonychia, increased heart rate (pulse), hypotension, lipothymia, dyspnea, asthenia, limb paresthesia and instability or depression.<sup>22,23</sup>

Oral clinical manifestations in patients with hemolytic anemias vary according to each patient, the most common ones described in the literature in patients with sickle cell anemia are: delay in the eruption, unusual periodontitis, alterations of the cells of the surface of the tongue, hypomineralization of the enamel and dentin.<sup>24</sup>

Patients who have their spleen removed are susceptible to infections, the spleen has macrophages, and these contribute to protection against infection and participate in phagocytosis of defective red blood cells. In this way, oral-dental infections should be prevented. Patients often present with burning, tenderness, and

ulcerations. At the oral mucosa level, it is pale, attributed to increased hemolysis of red blood cells due to the formation of sickle cells as well as atrophy of the tongue papillae and glossitis.<sup>25</sup>

Enamel hypoplasia may appear in the form of white spots on the tooth surface, causing greater susceptibility to caries. Osteoporosis and parallel trabeculae between the teeth, but not in edentulous areas.<sup>26</sup> The prevalence of dental caries and periodontal diseases is significantly higher in these patients due to the frequent and continuous use of medications that have sucrose in their composition, observing a high frequency of complications and hospitalizations caused by the absence of oral hygiene. Asymptomatic pulp necrosis has been reported, sickle cells can block the blood vessels supplying the pulp, with a possible result of necrosis.<sup>27</sup>

Osteomyelitis is the result of sickle cell anemia, it makes the blood more viscous, producing low blood flow, causing ischemic infarction and bone necrosis, rarely caused in the facial bones.<sup>28</sup>

The literature on stomatological manifestations in HD patients is very scarce. HD disease manifests with pale skin and mucosa with atrophy of the lingual papillae. It has been described that, at the dental level, there is dental dyschromia with a decrease in the size of the teeth.<sup>29</sup> Dyschromia, being a change of coloration in the tissues of the teeth, is related in patients with hemolytic anemias, such as fetal erythroblastosis that causes green, black or bluish discoloration, and enamel hypoplasia in primary teeth.<sup>30</sup>

There is very little literature on stomatological alterations in patients with thalassemia, but it has been described that modifications are found in the dental arches, malocclusion, gingivitis, caries, etc. Some of the symptoms that can alert the dentist to suspect a hemopathy (anemias): Pale skin, mucosa and nail bed, Jaundice (hemolytic



anemias), mucosal necrosis, tongue depapilation, atrophy of filiform papillae, burning or itching, burning, oral mucosa pain (stomatodynia), fissures and cracks in the lips and commissures, dysgeusia, petechiae and ecchymosis, dysphagia, deformation of the jaws and/or jaw (thalassemia major or Cooley's anemia).<sup>31</sup>

Exaggerated growth of the mandible and jaws, more marked in these latter bones that are observed with a particular prominence, manifests malocclusion. In intraoral radiographs, there is a widening of the bone trabeculate that alternates with the loss of some trabeculae and can be defined as osteoporosis. Thalassemia minor (heterozygous), as in thalassemia delta-beta, the symptoms are much milder or absent.<sup>32</sup>

At facial level, the presence of orbital hypertelorism is constant. These changes are what have given the Cooley or mouse face of patients with thalassemia. If transfusions have been performed from birth, up to 50% of patients may not present, or do so in an attenuated way, the aforementioned signs.<sup>33</sup> **Table 1**

Brandão et al. in 2018 conducted a study at a hematology center in Bahia, Brazil that aimed to assess the oral condition of children and adolescents with sickle cell anemia compared to the condition of healthy controls. The results showed that children and adolescents with sickle cell anemia had poor oral health compared to the healthy control group, presenting a higher level of dental caries and a lower buffer capacity.<sup>34</sup>

Carvalho et al. in 2015, conducted a study to investigate the association of sickle cell anemia (SCA) and sickle cell trait (SCT) with periodontal disease using clinical and radiographic evaluations. In the sample (n = 369) they selected and divided into two groups: exposed groups [HbSS (SCA genotype) and HbAS (SCT genotype) = 246] and an unexposed group (HbAA

= 123). HbAA consisted of individuals without SCA and SCT. The results showed that none of the periodontal parameters was associated with sickle cell anemia. And that sickle cell trait was associated with gingivitis and periodontitis. People with sickle cell trait had a lower dentobacterial plaque index (p = 0.044) but a higher stone index (p = 0.003) and greater alveolar bone loss (p = 0.010) compared to subjects in the HbAA group. They concluded that the sickle cell trait may act as a predictor for the establishment of periodontal diseases. There was no correlation between sickle cell anemia and periodontal diseases.<sup>35</sup>

Lira-Urbina et al. in 2017 described the rehabilitation treatment in a patient with a diagnosis of HS and ventricular septal defect and whose stomatological diagnosis was: ICDAS 4, 5, and 6, DPI of 100%, molar incisor hypomineralization and extrinsic stains due to ferrous fumarate. They concluded that the patient showed an abandonment in oral care, making the intervention of the pediatric stomatologist important for his rehabilitation, education, prevention and oral care.<sup>36</sup>

Siamopoulou-Mavridou et al. in 1992 conducted a study where 21 children with thalassemia major (TM) and 83 healthy children were examined for caries and gingivitis. Secretions from the general parotid were collected from each child. The result is that the dental caries experience is significantly greater in the TM group. The rate of paralysis flow in the TM patients is not statistically significant compared to the control group. However, the mean salivary concentration of phosphorus and IgA was severely lower in the TM patients. Furthermore, calcium and lysoenzyme levels were lower, but the differences were not different either. These results demonstrated an explanation for the greater dental caries and gingivitis observed in the group with TM.<sup>37</sup>

**Table 1.** Stomatological manifestations in patients with hereditary hemolytic anemias

	Signs	Symptoms
<b>Sickle cell anemia</b>	<b>At the bone level:</b> Osteoporosis Osteomyelitis <b>At the mucosa level:</b> Unusual periodontitis Pale mucosa Atrophy of lingual papillae Glossitis <b>At the dental level:</b> Dental caries Malocclusion pulp necrosis Enamel hypoplasia Hypomineralization (enamel and dentin) Delay in tooth eruption	Burning Sensitivity Ulcerations
<b>Hereditary spherocytosis (HS)</b>	<b>At the skin and mucosa level:</b> Skin and mucosa pallor Atrophy of lingual papillae <b>At the dental level:</b> Dental dyschromias Microdontics Dental caries Pulpitis	
<b>Thalassemia</b>	<b>At the bone level:</b> Hypertelorism Osteoporosis Deformation of the jaws and/or jaw <b>At the level of epithelial membranes:</b> Jaundice Paleness of skin and mucous Cissures and cracks in lips and corners Petechiae Ecchymosis Necrosis of the mucosa Lingual hair removal Atrophy of filiform papillae <b>At the dental level:</b> Dental caries Malocclusion	Stomatodynia Dysgeusia Dysphagia

Shadlinskaya and Zeynalova in 2019 carried out an investigation on “The evaluation of the prevalence and intensity of dental caries in patients with  $\beta$  thalassemia major” conducted at the Azerbaijan dental clinic, at the medical university and at the Thalassemia Center specialized in Baku, where they examined 295 children diagnosed with  $\beta$ -thalassemia major, aged 3-17 years in the main group, the comparison group was a control group consisting of 258 healthy children of the same

age in the main group. The results showed that in children with  $\beta$ -thalassemia major they had higher rates of prevalence and intensity of dental caries with a significant predominance of untreated teeth than children in the control group.<sup>38</sup>

The objective of this paper is to know the oral manifestations in patients with hereditary hemolytic anemias for an early diagnosis and personalized dental care.

## MATERIALS AND METHODS

A prospective observational cross-sectional descriptive study was carried out at the Hospital de Alta Especialidad del Niño Dr. Rodolfo Nieto Padrón, in children who attended the outpatient hematology and pediatric dentistry service during the period of June 4 to August 8, 2019. An *ad hoc* instrument was designed that consisted of three sections, the first section designed to empty the sociodemographic data of age and gender, which was obtained from the clinical record, the second section consisted of the hematological data of the participants, in this case it was taken from the clinical file, the third section consisted of an odontogram to know the oral and dental characteristics of the hard and soft tissues of the participants, to fill it, a clinical exploration of the oral cavity was performed with mirror and direct light. A unique and exclusive survey was conducted for this research. The data were analyzed in the SPSS® version 22 program where the study variables were analyzed with descriptive statistics and they were emptied into frequency tables.

## RESULTS

A total of 10 children and adolescents ranging in age from 1 to 13 years were examined (**Table 2**). It occurred in both genders, 5 children were

male and 5 female. The hereditary hematological disorders that appeared were sickle cell anemia and hereditary spherocytosis, 5/10 children presented sickle cell anemia and 5/10 hereditary spherocytosis.

**Table 3** shows the oral manifestations found in patients with hereditary hemolytic anemias, where it is shown that pale mucosal coloration was found more frequently with 90%, because they had a mean hemoglobin of 8.31 g/dL; 10% of the patients presented hypohidrosis in mucosa and 10% presented gingivitis due to poor oral hygiene in patients who are hospitalized. It was observed that 30% of the patients presented a Saburral tongue; 80% of the patients presented caries, which may be related to the hypomineralization present in 50% of the cases, since this makes dental organs more susceptible to caries.

**Table 3.** Oral manifestations in patients with hereditary hemolytic anemias (n = 10)

Manifestations	No.
<b>Intraoral</b>	
Mucosal pallor	9
Jaundice in mucosa	1
Hypohidrosis in mucosa	1
Gingivitis	1
Saburral tongue	3
Caries	8
Hypomineralization	5
Hypocalcification	1
Pulp necrosis	1
Supernumerary teeth	1
Class II bite	1
Dental crowding	4
Fenestrations	1
<b>Extraoral</b>	
Integumentary pallor	9
Integumentary jaundice	5
Jaundice and pale conjunctiva	1
Pupillary jaundice	1

**Table 2.** Age in years

Age	Frequency
1	2
4	2
5	1
6	1
7	1
11	2
13	1
Total	10



Pulp necrosis was present in 10% of patients, 10% of patients had supernumeraries. As a consequence of ineffective erythropoiesis, there are bone changes of which important malocclusions appear, in this case 40% of the patients presented crowding and 10% presented fenestrations. 90% of patients presented integument pallor more than jaundice since 50% of patients had jaundice in integuments and only 10% of patients presented jaundice and paleness in conjunctivae and jaundice in pupils.

## DISCUSSION

In this research, the distribution by gender was the same for both genders, which differs from that found by Marenco-Mercado, since in his study he shows that the female gender had a slight predominance with 63%.<sup>39</sup> Álvarez Fabio carried out an investigation in the Dominican Republic where he found that 55.6% of the patients suffered from sickle cell anemia at the ages of 26 and 35, in this investigation the distribution of patients between the ages of 1 to 13 with anemia of Sickle cells was 50%, which shows that this hematological disorder occurs in children and adults.<sup>40</sup>

One hundred percent of the patients included in this research were under 13 years of age, compared to what was found by Crisp and collaborators, since in their study it was identified that 88.7% had hereditary spherocytosis in children under 12 years. It has been mentioned that, in some patients, the first clinical manifestations occur between 4 and 6 years of age,<sup>25</sup> which differs with what was found in this investigation, since within 20% of the patients studied at 1 year of age they presented paleness and jaundice of integuments, icteric conjunctiva, pale mucosa and dental hypomineralization. In dental conditions, 10% of the patients presented pulp necrosis attributed to carious processes and denied presenting pain, since it is assumed that

there is a significant correlation between sickle cell anemia and asymptomatic pulp necrosis.<sup>41</sup> In the present investigation, 90% of the studied patients had caries, compared to what was found in the Emelemie Megningue investigation, where the 126 patients with sickle cell anemia had an DMF average's group (number of decayed, missing and filled teeth) of  $4.12 \pm 1.2$ ; which corresponded to a moderate prevalence of dental caries.<sup>42</sup>

Gutiérrez-Ramírez et al.<sup>41</sup> found more frequent oral manifestations, such as diastema between central incisors, multiple carious lesions, dental absences, as well as integumentary pallor, gum pallor, gingivitis and halitosis. This is consistent with findings in this study since the presence of caries was in 80%, paleness of mucosa and integuments in 90%, and gingivitis in 10%. Angles Olaguivel found in his research Gingivitis, multiple caries, reversible and irreversible pulpitis, tongue, pale skin and mucosa, which is consistent with what was found in this research since tongue was found in 30%.<sup>43</sup>

## CONCLUSIONS

Patients with hereditary hemolytic anemias are more susceptible to diseases at the oral cavity, so oral manifestations can guide an early diagnosis, sometimes oral manifestations can be the first sign of a hematological disorder and, therefore, at carrying out a dental treatment with a good general diagnosis, complications are avoided at the time of the patient's rehabilitation. It is important for dentist to promote oral hygiene education and initiate preventive treatment, since in the present investigation it was observed that the majority of patients presented hypomineralization, which leads to a high susceptibility to caries. Any person involved in the health area who is aware of the oral manifestations of this type of patient, should refer the patient to the dental office so that oral diseases do not progress.

Caries causes destruction of the hard tissues of the dental organs and also causes complications in food intake that are extremely important for the nutrition of these patients with hemolytic disorders, thus preventing the removal of affected dental organs since this type of treatments cannot be carried out in a private office, if not, they must be carried out in a hospital setting with the prior authorization of the hematologist, the dental surgeon must know the oral manifestations of this type of patient in order to provide personalized dental care according to their needs without jeopardizing their overall health and maximizing the benefits of dental treatment.

### Acknowledgments

To Hospital de Alta Especialidad del Niño Dr. Rodolfo Nieto Padrón, Universidad Juárez Autónoma de Tabasco and to the population studied, important elements for this research.

### REFERENCES

1. Ayala-Viloria AJ, González-Torres HJ, David-Tarud GJ. Anemia de células falciformes: una revisión. *Revista Científica Salud Uninorte* 2016; 32 (3): 513-527.
2. OMS. Epidemiología mundial de las hemoglobinopatías e indicadores de los servicios correspondientes. Disponible en: <https://www.who.int/bulletin/volumes/86/6/06-036673-ab/es/>.
3. Zúñiga CP, Martínez GC, González RL, Rendón CD, et al. Enfermedad de células falciformes: Un diagnóstico para tener presente. *Revista Chilena de Pediatría* 2018; 89 (4): 525-529. <http://dx.doi.org/10.4067/S0370-41062018005000604>.
4. Licona-Rivera TS, Arita-Chávez JR, Gámez-Alvarado JM, Witty-Norales SL, et al. Prevalencia de anemia drepanocítica en dos comunidades de Omoa, Cortés durante el año 2017. *Rev Cient Esc Univ Cienc Salud* 2017; 4 (2): 5-13.
5. Abanto-Rodríguez JL, Aranda-Ulloa JM, Araujo-Alvarado WS, Argomedeo-Alquizar CAG, et al. Anemia hemolítica en esferocitosis hereditaria: reporte de caso. *Revista Médica Trujillo* 2018; 13 (1): 27-34.
6. Carrillo-Esper R, Montes de Oca GA, Zárate-Vega V, Ojeda-Gómez S. Esferocitosis hereditaria. *Rev Invest Med Sur Mex* 2011; 18 (2): 64-66.
7. García-Rodríguez F, Rodríguez-Romo LN, Gómez-Peña Á, Martínez-González O, et al. Anemias hemolíticas hereditarias desde la perspectiva de un laboratorio de referencia del Norte de México. *Revista de Hematología* 2010; 11 (3): 136-140.
8. Tirado-Pérez IS, Zárate-Vergara AC. Anemia de células falciformes en pediatría: Revisión de la literatura. *Med UNAB* 2017; 20 (3): 374-382.
9. Pujadas-Ríos X, Viñals-Rodríguez LL. Enfermedad de células falciformes en el embarazo. *Revista Cubana de Obstetricia y Ginecología* 2016; 42 (2): 239-253.
10. Moraleda-Jiménez JM. *Pregrado de Hematología* (4ª ed.). Madrid, España: Luzán 2017.
11. Goldbard-Rochman D, Casaubon-Garcín PR, Baptista-González H, Lamshing-Salinas P. Esplenectomía en un lactante menor por esferocitosis hereditaria severa. *An Med (Mex)* 2017; 62 (4): 283-288.
12. Crisp RL, García E, Solari L, Rapetti MC, et al. Esferocitosis hereditaria: experiencia clínica. *Acta Bioquím Clín Latinoam* 2017; 51 (3): 307-18.
13. González-Anaya JA, Dávila-Torres JY. *Guía de Práctica Clínica Diagnóstico y Tratamiento de la Esferocitosis Hereditaria*. Instituto Mexicano del Seguro Social. 2014.
14. Macaluso JP (6 de noviembre de 2017). El Rincón de la Medicina Interna. Obtenido de: <https://www.elrincondelamedicinainterna.com/2017/11/volver-atras-girando-en-circulos-muy.html>.
15. López BML. Talasemia minor. *Lucha por vivir*. Archivos de la Memoria 2014; 11 (2).
16. Angastiniotis M, Lobitz S. Thalassemias: An overview. *Int J Neonatal Screen* 2019; 5(1): 16. doi: 10.3390/ijns5010016.
17. Hernández-Merino A. Anemias en la infancia y adolescencia. Clasificación y diagnóstico. *Pediatría Integral* 2016; XX (5): 287-296.
18. Serrano M, García P, Svarch, E, Menéndez V, Machín G. Crecimiento prepuberal en la drepanocitosis. *Revista Cubana de Hematología, Inmunología y Hemoterapia* 2016; 32 (3): 340-353.
19. Agramonte-Llanes OM, Hernández-Padrón C. Atención hematológica a la embarazada con drepanocitosis en el Instituto de Hematología e Inmunología. *Rev Cubana Hematol Inmunol Hemoter* 2016; 32 (1): 110-118.
20. González-García H, Garrote-Molpeceres R, Urbaneja-Rodríguez E. Anemias hemolíticas en la infancia. *Pediatría Integral* 2016; XX (5): 308-317.
21. Agarwal AM. Ankyrin mutations in hereditary. *Acta Haematologica* 2019; 141: 63-64.
22. Merino AH. Anemias en la infancia y adolescencia. Clasificación y diagnóstico. *Pediatr Integral* 2016; 20 (5): 287-296.
23. Cervera Á, Cela E, González A, Berruero R. 2015. *Guía de práctica clínica de la talasemia mayor e intermedia en pe-*

- diatría. (CEGE, Ed.) Obtenido de [www.cege.es](http://www.cege.es): <http://www.sehop.org/wp-content/uploads/2015/07/Gu%C3%ADa-de-Talasemia-SEHOP.2015.pdf>.
24. Aniceto-Freitas AB, Soares-Fernandes LC. Atendimento odontológico em pacientes com anemia falciforme. *Políticas e Saúde Coletiva* 2017; 2 (3): 49-60.
25. Rodríguez A, Hernández J, Escobar L. Anemia de células falciformes, manejo del paciente odontopediátrico. *Revisión bibliográfica. Odous Científica* 2018; 19 (2): 73-84.
26. Castellanos Suárez JL, Díaz-Guzmán LM, Lee G. Medicina en odontología: Manejo dental en pacientes con enfermedades sistémicas. *El Manual Moderno*, 2015.
27. Monty-Duggal AC. *Odontología pediátrica. El Manual Moderno*, 2014.
28. Letelier FC, Preisler EG, García CP, Salinas RF. Osteomielitis en el cóndilo mandibular y su relación con la anemia. *Int J Odontostomat* 2016; 10 (1): 49-53. <http://dx.doi.org/10.4067/S0718-381X2016000100009>.
29. Mojamed-Ali M. Manifestations buccales des hemopathies: Diagnostic precoce. These Pour Le Diplome D'état de Docteur en Chirurgie Dentaire 2011.
30. López-Larquin N, González-Vale L, Dobarganes-Coca AM. Recromias en dientes vitales con cambio de coloración. *Revista Electrónica Dr. Zoilo E. Marinello Vidaurreta* 2016; 41 (11).
31. Mercado S. Talasemia en la práctica de la clínica odontológica. *Rev Facultad Odontología* 2017; 27 (3): 16-20.
32. Santana-Garay JC. *Atlas de patología del complejo bucal* (2ª ed.). La Habana: Editorial Ciencias Médicas; 2010.
33. Cutando-Soriano A, Gil-Montoya JA, López-González Garrido JD. Las talasemias y sus implicaciones odontológicas. *Medicina Oral* 2002; 7: 36-45.
34. Brandão FC, Barreto O, Maia V, Santos M, et al. Association between sickle cell disease and the oral health condition of children and adolescents. *BMC Oral Health* 2018; 18: 169.
35. Carvalho HL, Thomaz EB, Alves CM, Souza SF. Are sickle cell anaemia and sickle cell trait predictive factors for periodontal disease? A cohort study. *J Periodontal Res* 2016; 51 (5): 622-9. doi. 10.1111/jre.12342.
36. Lira-Urbina T, Salazar-Cruz MA, Ochoa-Cáceres S. Manejo estomatológico en paciente con diagnóstico de esferocitosis hereditaria y comunicación interventricular. *Oral Revista BUAP* 2017; Suplemento No. 13.
37. Siamopoulou-Mavridou A, Mavridis A, Galanakis E, Vasakos S, et al. Flow rate and chemistry of parotid saliva related to dental caries and gingivitis in patients with thalassaemia major. *Int J Pediatr Dent* 1992; 2 (2): 93-97. doi. 10.1111/j.1365-263x.1992.tb00016.x.
38. Shadlinskaya R, Zeynalova G. The evaluation of the prevalence and intensity of dental caries in  $\beta$ -thalassemia major patients. *Dentistry* 2019; 9.
39. Marengo-Mercado G. Caracterización clínico epidemiológico de los pacientes con diagnóstico de anemias hemolíticas en el Servicio de Hematología del Hospital Infantil Manuel de Jesús Rivera "La Mascota" en el periodo comprendido enero 2011-diciembre 2015. Tesis para optar el título de pediatría (marzo de 2016).
40. Álvarez-Fabio M. Hallazgos ecocardiográficos en pacientes con anemia de células falciformes que asisten al departamento de hematología del hospital Doctor Salvador Bienvenido Gautier, Octubre 2017-Abril 2018. Tesis pos grado para optar por el título de especialista en hematología clínica. 2018.
41. Gutiérrez-Ramírez DA, Restrepo-Dorado AI, Muñoz GV, Buitrago-Galíndez J. Detección precoz de anemia de células falciformes por medio de un diagnóstico clínico y radiográfico oral. Reporte de caso. *Universitas Odontológica* 2015; 34 (72): 19-26.
42. Emelemie-Meningue N. Manifestations bucco-dentaires de la drépanocytose chez l'enfant et l'adolescent Camerounais. *Hématologie*, University de Yaoundé. Obtenido de <https://www.hsd-fmsb.org/index.php/hsd/thesis/view/259>.
43. Angles-Olaguivel MG. Pulpotomía usando Biodentine en paciente con esferocitosis hereditaria. Para optar el título de segunda especialidad profesional en Odontopediatría. 2018.