

Blinatumomab before haploidentical transplant in a child with refractory acute lymphoblastic leukemia.

Blinatumomab previo a trasplante haploidéntico en una niña con leucemia linfoblástica aguda resistente

Alberto Olaya-Vargas,¹ Roberto Rivera-Luna,² Yadira Melchor-Vidal,^{3,4} Cristina Cedeño-Cuellar,^{3,4} Haydeé Salazar-Rosales,^{3,4} Alberto Olaya-Nieto⁵

Abstract

The case of a 10-year-old patient with refractory pre-B acute lymphoblastic leukemia (ALL) who received two cycles of blinatumomab at 10 $\mu\text{g}/\text{m}^2$, escalating up to 15 $\mu\text{g}/\text{m}^2$, is described. At the end of the second cycle, complete hematological remission was achieved, as evidenced by cytomorphology and minimal residual disease. Afterward, the patient received a haploidentical transplant from a paternal donor and cyclophosphamide therapy for consolidation; currently, she is at +365 days from transplant and in complete remission with 100% complete chimerism. The patient presented with late cytokine release syndrome as a side effect of blinatumomab and acute graft-versus-host disease grade III, both of which were successfully treated, and the patient remains asymptomatic.

KEYWORDS: Acute lymphoblastic leukemia; Haploidentical transplant; Blinatumomab.

Resumen

Se describe el caso de un paciente de 10 años de edad con leucemia linfoblástica aguda (LLA) resistente al tratamiento con quimioterapia, quien recibió dos ciclos de blinatumomab a dosis de 10 $\mu\text{g}/\text{m}^2$, aumentando hasta 15 $\mu\text{g}/\text{m}^2$ por dos ciclos. Al final del segundo ciclo, se logró remisión hematológica completa, que fue documentada por citomorfología y la enfermedad residual mínima (ERM). Posteriormente, la paciente recibió un trasplante haploidéntico con ciclofosfámidas postrasplante para prevención de la enfermedad injerto vs hospedero de un donante paterno como terapia de consolidación; actualmente, la paciente está en el día +365 del trasplante y en remisión completa con quimerismo completo. La paciente tuvo síndrome de liberación tardía de citocinas como efecto secundario de blinatumomab y enfermedad aguda de injerto contra huésped grado III, que se trataron con éxito; actualmente el paciente permanece asintomático.

PALABRAS CLAVE: Leucemia linfoblástica aguda; trasplante haploidéntico; blinatumomab.

¹ Program Director.

² Director of Hem/Oncology.

³ Bone Marrow Transplant Unit, National Institute of Pediatrics, Mexico City.

⁴ Bone Marrow Transplant Unit, ABC Medical Center, Mexico City.

⁵ Student of Medicine, St. Luke University, Mexico City.

Received: February 28, 2019

Accepted: May 9, 2019

Correspondence

Alberto Olaya Vargas
alberto.olaya@yahoo.com.mx

This article must be quoted

Olaya-Vargas A, Rivera-Luna R, Melchor-Vidal Y, Cedeño-Cuellar C, et al. Blinatumomab before haploidentical transplant in a child with refractory acute lymphoblastic leukemia. Hematol Méx. 2019 July-September;20(3):235-239. <https://doi.org/10.24245/rhematol.v20i3.2974>

BACKGROUND

Acute lymphoblastic leukemia (ALL) is the most common childhood cancer.¹ This type of leukemia is highly sensitive, with a remission rate and a long-term disease-free survival rate of 80-90% and, consequently, a high probability of achieving a cure.² However, patients who relapse and become refractory to conventional chemotherapy have only an approximately 30-40% chance of achieving long-term remission.³

Allogeneic bone marrow transplant constitutes a treatment option for patients who relapse and become refractory to conventional treatment; however, one of the major problems with this treatment is the identification of a histocompatible donor among family members or in a donor bank.⁴ In cases where no histocompatible donors are found, an haploidentical donor is the alternative. One of the most important factors for achieving positive results is the disease status before transplant; patients in complete remission with an MRD < 0.002 log before transplant have a better prognosis.⁵ Blinatumomab has proven to be effective in achieving remission in patients with pre-B CD19+ ALL who relapse or become refractory to treatment.⁶

This current report describes the therapeutic efficacy and adverse events in a patient with pre-B CD19+ ALL treated with blinatumomab to achieve molecular remission and a subsequent haploidentical transplant as consolidation to improve disease-free survival.

CLINICAL CASE

A 10-year-old Mexican female with a diagnosis of standard-risk pre-B ALL. The patient was treated with the St. Jude XIIIB regimen, and complete remission was achieved during 30 months of the chemotherapy protocol. The child remained in complete remission for 67 months. Then, relapse

occurred in the bone marrow with 95% lymphoblasts; positive signals for CD19, CD20, CD22, CD79a, CD38, CD45, and HLA-DR; DNA index: 4.9; cytogenetics 45 XX (- 6) (- 9) (9;12)/46 XX; and spinal fluid without infiltration. The patient was treated with the BFM 90 regimen; there was no response at 4 weeks, with persistent lymphoblasts in the bone marrow and an elevated MRD. The decision was made to perform rescue with the IDA-FLAG regimen, which was well tolerated; however, after two cycles, the patient continued to present with 58% lymphoblasts and a high MRD. At this point, the patient's relatives chose palliative care with low-dose prednisone.

A haploidentical transplant was proposed due to the lack of an HLA identical donor. As a strategy to achieve remission, blinatumomab 10 µg/m² in 250 cc of saline was infused for 48 hours (actual dose, 5 µg/m²), and then, the dose was increased to 15 µg/m². During the 28 days of continuous infusion, the patient presented with hyperthermia without hemodynamic impact during the first 48 hours, and between days 16 and 28 the patient presented with dysesthesias that improved with the use of analgesia. She continued treatment without complications. However, 15 days after the conclusion of the 1st cycle, she presented at the hospital emergency room in poor general condition with diffuse abdominal pain, vomiting, fever, pancytopenia, metabolic acidosis and hypovolemic shock. An infection was suspected, and the inflammatory marker results requested on admission revealed ferritin 2649 ng/mL, C-reactive protein (CRP) 1.8 mg/dL, procalcitonin (PCT) 0.2 ng/mL and erythrocyte sedimentation rate (ESR) 23 mm/hour; chest X-ray, abdominal ultrasound, and sepsis work-up were also performed. Antibiotic therapy was started with vancomycin and cefepime, but the patient presented with acute exacerbation. At 48 hours, significant increases in some acute-phase markers were observed: ferritin 4624 ng/mL, CRP 5 mg/dL, PCT 0.2 ng/mL and ESR 45 mm/hour

(**Figure 1**). The cultures were negative, so additional acute-phase markers were examined, and a chest X-ray was performed. The latter revealed bilateral pleural effusion predominantly in the right hemithorax. The echocardiogram showed pericardial effusion and cardiomegaly.

Six hundred thirty milliliters of a fluid characteristic of transudate was obtained by thoracentesis, and no signs of infection were documented; thus, the diagnosis of late cytokine release syn-

drome was made. Noninvasive ventilatory support was established with dexamethasone 6 mg/m² and gammaglobulin 1 g/kg/day. After 5 days of this treatment, clinical improvement was noticed, including in respiratory function. The patient was discharged completely asymptomatic.

After the first cycle of blinatumomab, a negative MRD was noticed. A second cycle of blinatumomab was administered without adverse effects, and consolidation was performed with

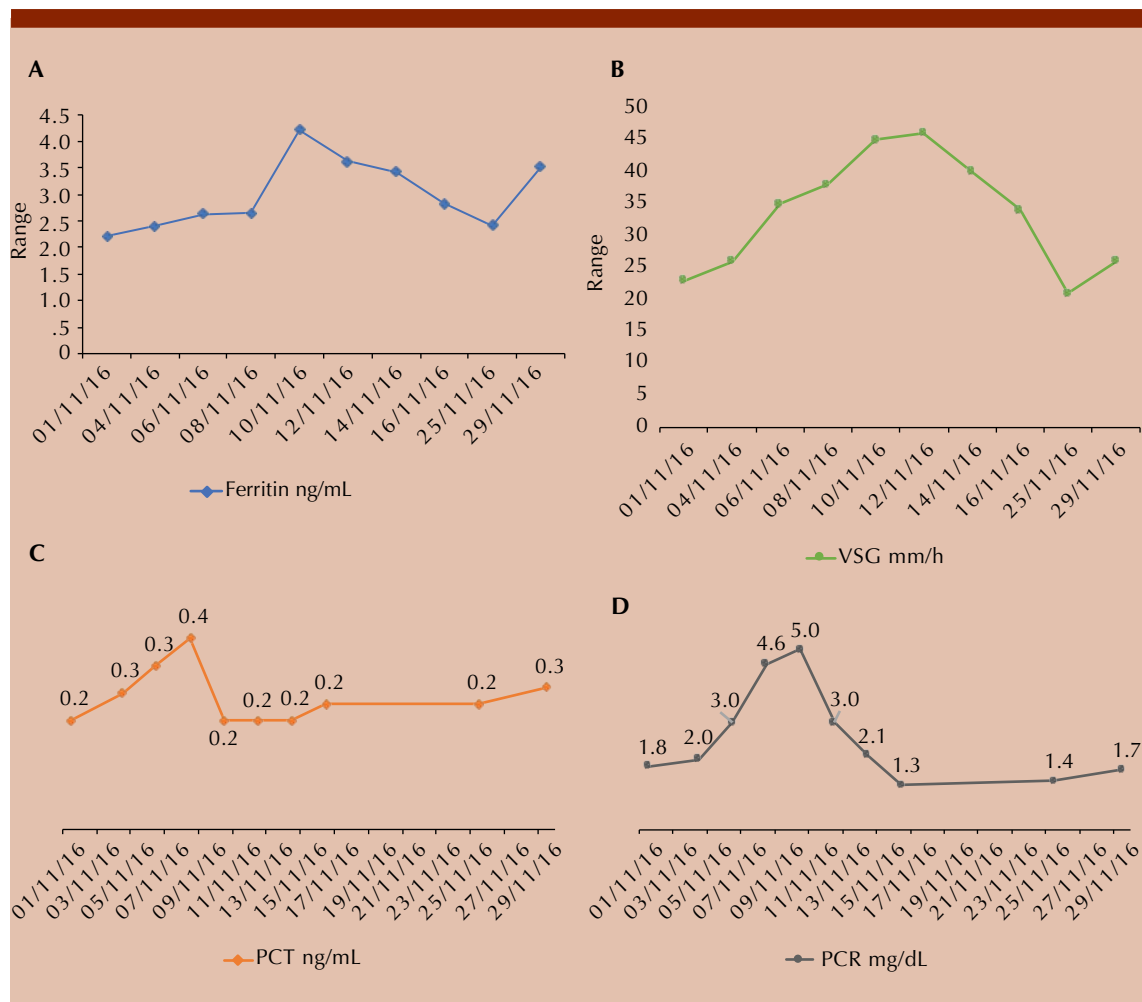


Figure 1. Kinetics of inflammatory markers during late release syndrome 15 days after completing the first cycle of blinatumomab. **A.** Serum ferritin levels. **B.** Erythrocyte sedimentation rate. **C.** Serum procalcitonin levels. **D.** C reactive protein levels.

haploidentical transplant from a paternal donor with A-positive Rh iso-group and cytomegalovirus (CMV)-negative donor and recipient status. The conditioning regimen consisted of a total body irradiation scheme at 200 cGy/day for three days, followed by cyclophosphamide and etoposide; the patient then received 8×10^6 CD34⁺ cells and prophylaxis for graft-versus-host disease (GVHD) with cyclophosphamide, mycophenolate mofetil and tacrolimus beginning on day 5. The myeloid cell graft was documented on day +14, at that point 100% donor chimerism was reported. Complications from transplantation included acute GVHD at the intestinal level that was refractory to corticoids and warranted treatment with infliximab; a good response was achieved, and the patient remained in complete remission with 100% donor chimerism at 365 days.

DISCUSSION

In patients with refractory ALL, treatment focuses on the highly myelotoxic polychemotherapy with the intention to destroy all the leukemic clones. However, extended periods of aplasia can lead to serious infections with a high mortality rate. One of the most promising therapies is the bi-specific monoclonal anti-CD3-CD19 antibody blinatumomab, which causes the formation of a cytolytic synapse mediated by the release of perforin and granzymes from cytoplasmic granules in T lymphocytes, in addition to the release of inflammatory cytokines that promote the proliferation of these cells.⁷ Blinatumomab has proven to be effective in achieving remission in patients with pre-B CD19⁺ ALL who relapse or become refractory to treatment when administered in 5 cycles at 15 $\mu\text{g}/\text{m}^2$ per day for 28 days.⁶ Blinatumomab is proposed as a bridge treatment prior to transplant, especially considering the potential of achieving full remission. Such is the case for our patient who presented with negative MRD

after the first cycle of blinatumomab, despite refractoriness to complete molecular remission. However, 19 days after the end of the first cycle, the patient developed symptoms consistent with late cytokine release syndrome, while only mild fever and arthralgia were recorded during the infusion.

In our case, a clinical picture highly suggestive of septic shock emerged without any documentation of bacterial infection but with a noted progressive increase in ferritin, CRP, ESR, and PCT as acute-phase markers (**Figure 1**). Despite the prescription of empirical antibiotic therapy, the symptoms did not disappear; clinical improvement was observed only after the administration of steroids and gammaglobulin. These data suggest a late presentation of cytokine release syndrome.

There is limited evidence of this phenomenon, although some authors have mentioned the presence of mutations in the perforin gene in CD3⁺ T lymphocytes as justification for the late release of cytokines.

The advantages of haploidentical transplantation are widespread availability, fast access, and accessibility to the donor for cell therapies if required.⁸ This type of transplant also presents greater immunological barriers.⁹ The use of cyclophosphamide posttransplant (50 mg/kg at +3 and +4 days) promotes immune tolerance and hence reduces the rate of GVHD.¹⁰ Subsequently, several pediatric groups have tried this strategy and achieved overall survival rates of 60-70%, progression-free survival rates of 60-65%, and mortality rates of less than 10%.¹¹

The use of both therapies may be an effective and less toxic option for children with refractory/relapsed ALL.

REFERENCES

1. Hunger SP, Mullighan CG. Acute Lymphoblastic Leukemia in Children. *N Engl J Med* 2015;373:1541-52.
2. Hunger SP, Lu X, Devidas M, Camitta BM, Gaynon PS, Winick NJ, et al. Improved survival for children and adolescents with acute lymphoblastic leukemia between 1990 and 2005: a report from the Children's Oncology Group. *J Clin Oncol* 2012;30(14):1663-69.
3. Madhusoodhan PP, Carroll WL, Bhatla T. Progress and prospects in pediatric leukemia. *Curr Probl Pediatr Adolesc Health Care* 2016;46:229-41.
4. Majhail NS, Farnia SH, Carpenter PA, Champlin RE, Crawford S, Marks DI, et al. Indications for autologous and allogeneic hematopoietic cell transplantation: guidelines from the American Society for Blood and Marrow Transplantation. *Biol Blood Marrow Transplant* 2015;21:1863-1869.
5. Klingebiel T, Cornish J, Labopin M, Locatelli F, Darbyshire P, Handgretinger R, et al. Results and factors influencing outcome after fully haploidentical hematopoietic stem cell transplantation in children with very high-risk acute lymphoblastic leukemia: impact of center size: an analysis on behalf of the Acute Leukemia and Pediatric Disease Working Parties of the European Blood and Marrow Transplantation. *Blood* 2010;115:3437-3446.
6. Von Stackelberg A, Locatelli F, Zugmaier G, Handgretinger R, Trippett TM, Rizzari C, et al. Phase I/phase II study of blinatumomab in pediatric patients with relapsed/refractory acute lymphoblastic leukemia. *J Clin Oncol* 2016;34(36):1-9.
7. Matthew J Newman, Dina J Benani. A review of blinatumomab, a novel immunotherapy. *J Oncol Pharm Practice* 2016;22:639-645.
8. Mehta P, Davies M. Hematopoietic cell transplantation for acute lymphoblastic leukemia in children. In: Forman S, Negrin R, Antin JH, Appelbaum FR. *Thomas' Hematopoietic cell transplantation*. 5th ed. CA, USA: John Wiley & Sons, 2016;600-613.
9. Reisner Y, Aversa F, Martelli MF. Haploidentical hematopoietic stem cell transplantation: state of the art. *Bone Marrow Transplant* 2015;50(2):S1-S5.
10. Luznik L, Bolaños-Meade J, Zahurak M, Chen AR, B. Smith D, Brodsky R, et al. High-dose cyclophosphamide as single-agent, short-course prophylaxis of graft-versus-host disease. *Blood* 2010;115(16):3224-3230.
11. Berger M, Lanino E, Cesaro S, Zecca M, Vasallo E, Faraci M, et al. Feasibility and outcome of haploidentical hematopoietic stem cell transplantation with post-transplant high-dose cyclophosphamide for children and adolescents with hematologic malignancies: An AIEOP-GITMO Retrospective Multicenter Study. *Biol Blood Marrow Transplant* 2016;22:902-09.